

Review

Open Access



Perspectives of prevention and treatment of parastomal hernia-what do we really know and where should we go?

Dieter Berger

Spital Männedorf, Asylstrasse 10, Männedorf CH-8708, Switzerland.

Correspondence to: Prof. Dieter Berger, Attending Surgeon, Spital Männedorf, Asylstrasse 10, Männedorf CH-8708, Switzerland. E-mail: dieter.berger@hin.ch

How to cite this article: Berger D. Perspectives of prevention and treatment of parastomal hernia-what do we really know and where should we go? *Mini-invasive Surg* 2023;7:24. <https://dx.doi.org/10.20517/2574-1225.2023.30>

Received: 30 Mar 2023 **First decision:** 12 May 2023 **Revised:** 14 Jun 2023 **Accepted:** 25 Jun 2023 **Published:** 29 Jun 2023

Academic Editors: Luca Gordini, R. Fortelny **Copy Editor:** Dan Zhang **Production Editor:** Dan Zhang

Abstract

Parastomal hernia is a frequent complication after ostomy formation, causing a significant reduction of the quality of life of patients. In contrast to surgical dogmas dealing with the surgical technique of ostomy formation, mesh-based prophylaxis of parastomal hernia seemed to be effective, leading to the strong recommendation in the European Hernia Society(EHS) guidelines. More recent studies do not favor prophylaxis of parastomal hernia anymore, mainly due to the lack of clearly differentiating the techniques. The mostly used keyhole technique (flat mesh) cannot be equated with the “chimney technique” (3-dimensional mesh) that can be easily performed laparoscopically. Very recent results of the Finnish Randomized Study showed a dramatic reduction of parastomal hernia using the chimney technique. Concerning therapy of parastomal hernia, the chimney technique was also revealed to be effective. The laparoscopic “sandwich technique” should also be used therapeutically with very promising mid- and long-term results and seems to be superior to any other approaches. In a conclusion, investigating the prevention of parastomal hernia should clearly differentiate between the keyhole and chimney techniques and adopt strict technical standardization. Therapy of parastomal hernia should be based on the most effective sandwich or the chimney technique in specialized centers, according to recent registry results. Both techniques are based on the intraperitoneal placement of meshes requiring 3-dimensionality or the possibility of overlapping two meshes. Up to now, these requirements are only fulfilled by meshes made by polyvinylidene fluoride.

Keywords: Parastomal hernia, repair, prevention, surgical technique, mesh



© The Author(s) 2023. **Open Access** This article is licensed under a Creative Commons Attribution 4.0 International License (<https://creativecommons.org/licenses/by/4.0/>), which permits unrestricted use, sharing, adaptation, distribution and reproduction in any medium or format, for any purpose, even commercially, as long as you give appropriate credit to the original author(s) and the source, provide a link to the Creative Commons license, and indicate if changes were made.



INTRODUCTION

The occurrence of complications after ostomy formation has been described for a long period of time. In 1994, the incidence of peristomal complications was retrospectively described to increase to almost 70% depending on the type of ostomy and the underlying disease after ten years^[1,2]. The skin is the predominantly affected location after ileostomy, and hernias were described in about 37% (colostomy) and 16% (ileostomy). Similar data have been published more recently, indicating the absence of any progress concerning the incidence of stoma-related problems^[3] during the last 30 years. Urostomies are also prone to develop parastomal hernias to a similar extent^[4-8]. After the formation of an ileal conduit, a parastomal hernia will occur in up to 30% after observation periods of only four years. Keeping in mind that the occurrence of parastomal hernia increases continuously with time^[1,2], these results represent only the beginning part of the reality. Whereas skin problems can usually be controlled by improved stoma care, if a hernia is not causing stoma care problems, the parastomal hernia should be prevented or treated by surgical means. Despite the frequency, there is an almost complete lack of knowledge about what happens with the patient with a parastomal hernia over time. Without scientific support, it is generally believed that parastomal hernia is mostly asymptomatic. In 2009, Moreno-Matias *et al.* described a simple radiological classification of parastomal hernia, evaluating 75 colostomy patients^[9]. Thirty-three patients revealed a hernia by clinical examination. Twenty-seven (88%) reported associated symptoms. More detailed results investigating the quality of life showed that patients with a stoma had a significantly lower quality of life, which is further reduced when a hernia is present^[10-12].

Risk factors that enhance the rate of parastomal hernia have been extensively described. However, the results are not completely consistent^[6,7,13]. Body mass index and female gender are uniformly defined as contributing factors. Additionally, increasing age, larger aperture size, and larger waist circumference seem to play an important role. There is obviously no difference between urological and intestinal ostomies in this regard. The role of ostomy-associated atrophy of the rectus muscle and the accompanying midline shift is not clear^[14,15], but it seems to be an interesting factor interfering with the occurrence of parastomal hernia.

In 2013, data from the Danish Hernia Database demonstrated a 13.2% reoperation rate and a 6.3% mortality rate after parastomal hernia repair. Emergency procedures were identified as the strongest factor correlated with both reoperation and mortality^[16]. However, in 2018, non-operative strategies were recommended due to the unsatisfying results of parastomal hernia repair^[17]. In a multicenter evaluation of 80 patients, a recurrence rate of 55% was established, with 91% of patients with recurrence requiring re-repair. Additionally, 21% of non-surgical patients crossed over to the surgical group. Based on these findings, the authors concluded that non-operative treatment may be a better choice. However, to definitely support that point of view, scientific data about the natural course of parastomal hernia comprising an adequate number of patients are needed, but up to now, such data are not available.

Realizing the association of parastomal hernia with reduced quality of life, the lack of knowledge about the natural course, and the high complication rate of elective and especially non-elective repair, it is obvious that effective prevention and treatment strategies are urgently needed.

PREVENTION

Originally, any surgical measures to prevent the occurrence of parastomal hernia were based on technical details such as strict transrectal ostomies or extraperitonealization of the stoma loop. However, up to now, there is no real evidence of whether these modifications are really effective because of the lack of scientifically adequate data^[18,19]. In 2004, Janes *et al.* described the results of the first randomized study comparing a simple colostomy with a mesh-augmented colostomy^[20]. A lightweight polypropylene mesh

was centrally incised to allow the passage of the stoma-related bowel and placed in a retromuscular position. The diagnosis of parastomal hernia was established by clinical investigation. After 27 patients in each group, the ethics committee stopped the trial because the rate of parastomal hernia was drastically reduced in the mesh group. After one year, 13 out of 26 patients without a mesh developed a hernia compared with one out of 21 patients with a prophylactic mesh. It should be pointed out that the described technique is similar to the “keyhole technique” originally described for the repair of parastomal hernia. During the following years, a lot of observational and randomized controlled studies were published, leading to the Guidelines of the European Hernia Society in 2017, which strongly recommend a prophylactic mesh during the creation of end colostomies^[21]. Further analyses of existing randomized studies, including newer ones, were not able to find differences favoring the prophylactic use of meshes^[22]. The authors explained the inconsistent results with different techniques in terms of different meshes, different mesh placements, and different diagnostic tools and concluded that based on the available data in 2020, a prophylactic mesh could not be recommended. In a more recent systematic review, McKechnie *et al.* calculated a significant reduction of parastomal hernia in the mesh group^[23]. However, analyzing the studies published during the last five years, there was no difference in favor of prophylactic meshes anymore.

How can these obvious contradictions be explained? The diagnostic value of the clinical examination is lower compared to computed tomography (CT) or ultrasound imaging^[24]. Moreno-Matias previously described this aspect when establishing the radiologically based classification of parastomal hernia^[9]. He could also point out that the clinical relevance of clinically established hernias is more pronounced than in cases with only radiologically diagnosed hernias. A Finnish randomized controlled trial (RCT) using intraperitoneal keyhole prophylaxis demonstrated a clinical benefit that was no more present when patients with radiologically diagnosed parastomal hernia were included^[25]. Another aspect concerns the observation period. It seems to be clear that the prophylactic mesh delays the occurrence of parastomal hernia^[26]. The long-term results of this RCT after five years showed no statistical difference concerning the rate of parastomal hernia between the groups; however, there was a clear delay of the onset of the hernia in the mesh group. Generally, the mesh groups proved to be less symptomatic, underlining the above-mentioned results of fewer symptoms when the hernia is only detected by CT. Additionally, the methodology of performing systematic reviews and meta-analyses is subject to debate. In a comprehensive review, Garcia-Alamino *et al.* found that eight out of 14 systematic reviews meeting the inclusion criteria and dealing with the prevention of parastomal hernia had a generally low quality with a high risk of bias^[27].

Technical aspects should also be kept in mind, as most studies are based on the keyhole technique. In this technique, a synthetic non-resorbable mesh with a central hole, usually incised by the surgeon himself, is placed either retromuscularly or intraperitoneally. However, for the repair of existing parastomal hernias, the keyhole technique was no more recommended. There is the only hypothetical explanation that the shrinkage of the mesh induces an enlargement of the central opening, ending up in a recurrent hernia. This hypothetical explanation may also be true for the prophylaxis of parastomal hernia. When taking into account that small-pore meshes do shrink more than large-pore structures^[28], there is another point of heterogeneity in these studies.

In a few observational studies, the role of a funnel-like mesh in preventing parastomal hernia is described with promising results. The material used for the mesh is polyvinylidene fluoride, which exhibits some advantages over polypropylene not only in terms of foreign body reaction^[28,29]. The main difference to the above-described studies is the fact that this technique is definitely not a keyhole technique, as shown in [Figure 1](#). The mesh is implanted intraperitoneally with the funnel surrounding the stoma loop for 2.5 or 4 cm, depending on the structure used. When believing the above-described hypothesis about the keyhole

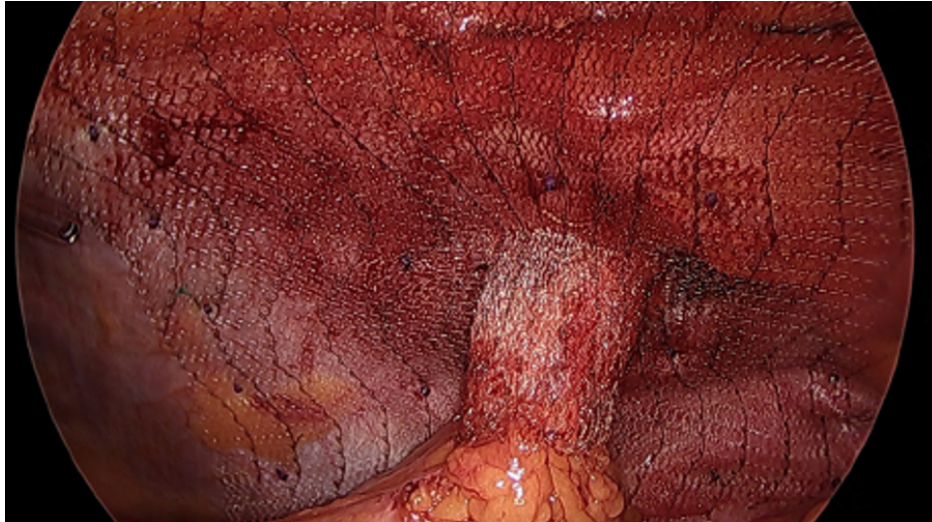


Figure 1. Intra-abdominal view of the chimney technique for prophylaxis of parastomal hernia with the Dynamesh IPST® with a 4 cm funnel in a patient with terminal sigmoidostomy. The mesh is fixed by resorbable tacks (blue ones) using a double crown

technique, possible shrinkage of the mesh will not increase the diameter of any keyhole but only shorten the length of the funnel. Therefore, with a longer funnel, 4 cm, the procedure should be even more effective, and this structure should be recommended. In a recent review, this technique for prophylaxis and therapy of parastomal hernia and the relevant literature are described in more detail and compared with the alternative keyhole technique^[30].

After the described promising results of observational studies, a well-designed RCT is already finished in Finland^[31] using the 3-dimensional implant known as the chimney trial. Therefore, according to the study, this technique should be called the “chimney technique” and clearly differentiated from the keyhole approach. The one-year results have been demonstrated at the annual meeting of the European Hernia Society. At that time point, the hernia rate was 2/60 (3%) in the mesh group and 30/62 (48%) in the control group. The diagnosis was established by CT. So, the ethics committee finished the study due to the highly significant benefit of the implant. The publication of the definitive findings from the chimney trial is eagerly anticipated this year and will revolutionize the field of parastomal hernia prophylaxis.

A further approach to evaluate the role of prophylaxis is through a well-designed registry or major cohort study that exactly documents the surgical details of stoma formation^[32]. This would allow for a better evaluation of less used techniques, such as SMART (Stapled Mesh StomA Reinforcement Technique)^[33], in comparison to the keyhole and chimney technique. Despite the not completely clear conclusions, the use of a prophylactic synthetic mesh will significantly reduce the lifetime costs^[34] for patients with end colostomy due to rectal cancer!

REPAIR

Generally, the parastomal hernia is not only a mechanical but also, more important, a biochemical problem, similar to incisional hernias^[35]. Similar changes of the extracellular matrix have also been described in patients developing a parastomal hernia^[36]. Therefore, the obvious conclusion is the necessity of a permanent augmentation of the abdominal wall because the scar will not be stable enough to prevent a hernia. Clinically, it has been clearly shown that suture-based repairs of parastomal hernia are associated with a high recurrence rate^[37]. Mesh-based repairs can be performed by open surgery, laparoscopic

techniques, or using robotic approaches. Additionally, the application of the mesh can differ widely. There exists the possibility of placing the mesh in an onlay, sublay (retromuscular), and intraperitoneal position. Furthermore, flat meshes can be incised to perform the keyhole technique in these positions. Another alternative is the Sugarbaker technique^[38], originally described for open surgery, with adequate lateralization of the stoma loop can be used. This technique was very early adopted laparoscopically^[39,40]. In the meantime, the minimal-invasive extraperitoneal “Sugarbaker technique” has been introduced^[41], which is highly suitable for robotic use^[42].

The literature contains a lot of case reports demonstrating the authors’ own techniques or modifications of preexisting approaches. However, major series of well-standardized procedures are scarce. Nonetheless, some reviews aimed to elucidate the effectivity of the different techniques. Hansson *et al.* described the superiority of the Sugarbaker technique compared to the keyhole technique. Our own experience, after four years of laparoscopic Sugarbaker repair, revealed unacceptable recurrence rates^[37,40]. When analyzing the patients suffering from recurrence, we found that the recurrence always occurred laterally, and the previous fascial defect was also located more lateral to the stoma site. We concluded that the lateralized stoma-related bowel preventing direct contact of the mesh with the abdominal wall does not stabilize it. So, the defect can grow over time, leading to a recurrence. To address this, we found that the combination of the keyhole technique to stabilize the lateral abdominal wall with the Sugarbaker technique, which covers the medial part and can overlap the midline if necessary, should be effective, which proved to be true, as shown in [Figures 2-4](#).

In the meantime, the sandwich technique has also been proposed for parastomal hernia after urostomies^[11]. Due to the complexity of the sandwich technique, the chimney technique was adapted for therapeutic purposes^[30,43], as shown in [Figure 1](#). Originally, the chimney technique was mainly performed as a hybrid procedure. After laparoscopic adhesiolysis, the stoma was excised, the parastomal defect was closed after resection of the hernia sac, and the 3-dimensional mesh was pulled over the mobilized stoma-related bowel and replaced intra-abdominally. The mesh could be fixed laparoscopically. The technique can be used in open surgery as well with augmentation of the median line. Sometimes, the 3-dimensional mesh was incised to avoid excision of the stoma and closed laparoscopically, which has been described anecdotally. To avoid incision of the Dynamesh IPST®, today, a preincised structure with enforced incision lines is commercially available (Dynamesh IPST R’).

A recent nationwide analysis after a median observation time of 39 months demonstrated the superiority of the sandwich and chimney techniques in comparison to Sugarbaker, keyhole, or other approaches^[44]. The recurrence rates are summarized in [Table 1](#). The details of this nationwide study clearly demonstrate the main problems associated with parastomal hernia repair. During a ten-year period, 235 patients with parastomal hernia have been operated on in nine hospitals, which means two to three patients per year per hospital. The overall complication rate amounted to 26.3%. The authors concluded that the recurrence rates are unacceptably high while the patient load is very low. I would like to add that the complication rate is also unacceptably high.

A Danish nationwide analysis before and after the centralization of parastomal hernia repair to five centers, which took seven years, demonstrated an increasing amount of patients, a reduction of emergency cases, and improved outcomes of emergency cases after centralization^[45]. So, it is absolutely clear that the repair of parastomal hernias should be performed by specialized surgeons in specialized centers providing an adequate caseload.

Table 1. Techniques and results of parastomal hernia repair in Finland

	Keyhole	Sugarbaker	Sandwich	Chimney
Frequency of use	16.3%	38.8%	15.4%	8.3%
Recurrence rate	35.9%	21.5%	13.5%	15%

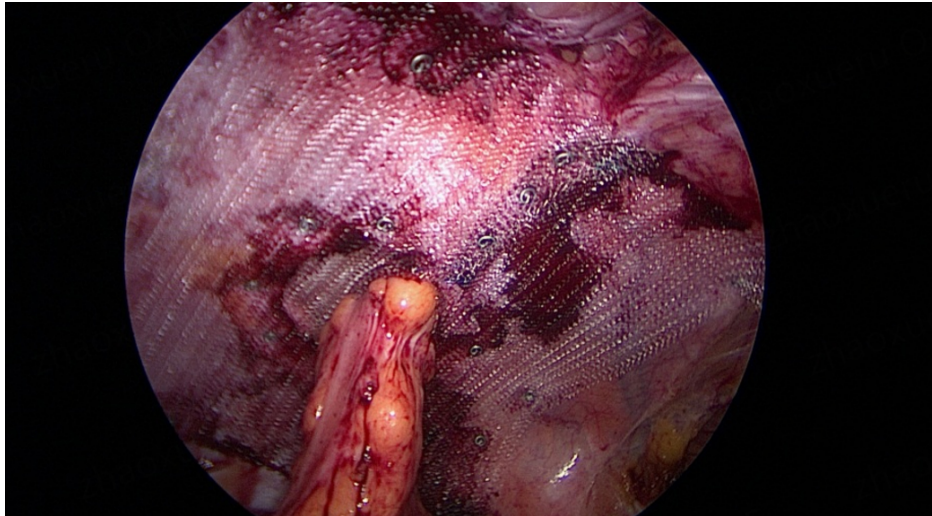


Figure 2. Keyhole repair as the first step of the “Sandwich technique”. The incised keyhole mesh (Dynamesh®) is put around the ostomy, closed by two non-absorbable sutures and non-absorbable tacks, and finally fixed every 3 cm at the edge of the mesh.

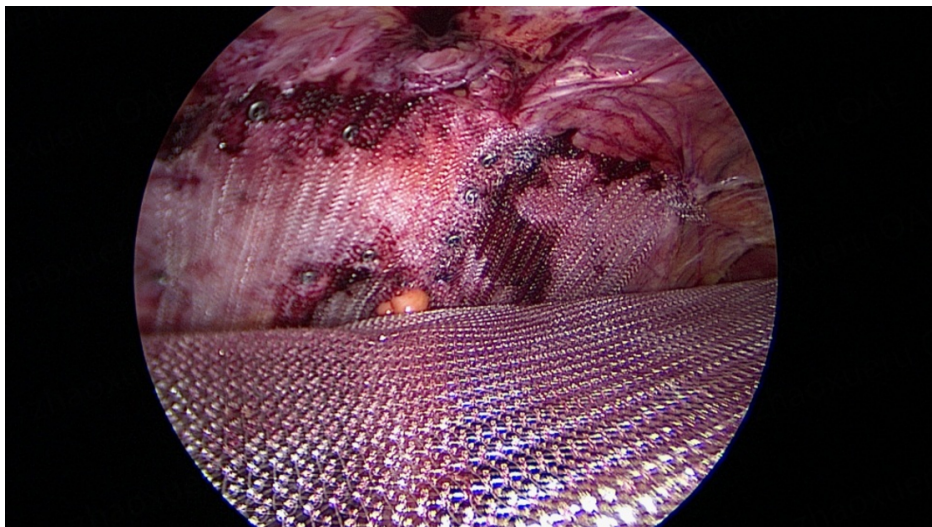


Figure 3. Placement of the “Sugarbaker”-mesh. Another Dynamesh® is placed above the keyhole mesh in a sandwich-like manner according to the Sugarbaker technique, covering the area between the midline and, sometimes, to the lateral edge of the keyhole mesh. So, the stoma-related bowel is fixed between the two meshes for at least 5 cm, better 7 cm.

The next point arising from the Finnish data concerns the variety of techniques used. Together with the low patient load under non-centralized conditions, it is almost impossible to compare the data of different techniques. Furthermore, it is unknown whether a special technique is really corresponding to the original description. In this context, it is worthwhile to have another look on the prevention of parastomal hernia. The chimney trial is based on a completely standardized mesh implantation procedure^[31], with only one

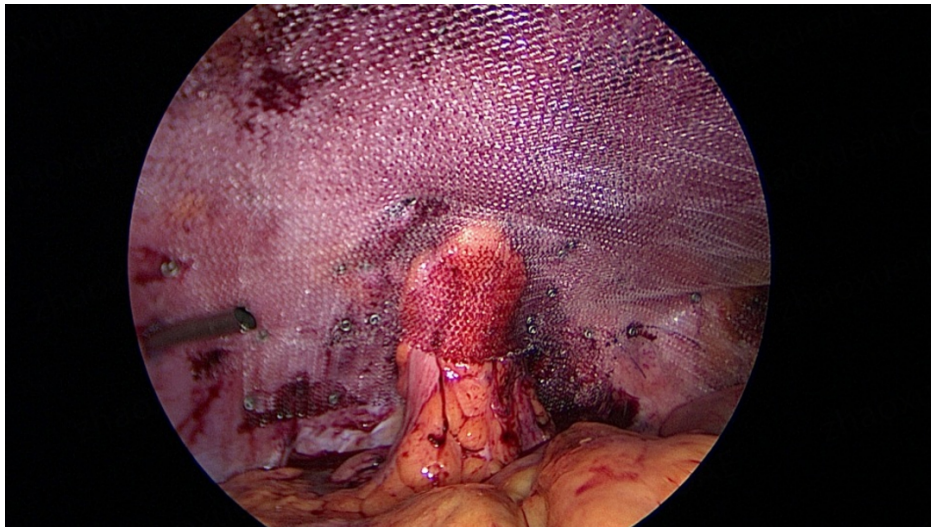


Figure 4. A final aspect of the “Sandwich technique”. The final picture demonstrates the stoma-related bowel lateralized between two meshes and fixed with two rows of tacks beside the intestine for 5 cm.

structure used throughout the study. That should be the way also for the repair of parastomal hernia.

With upcoming robotic use, the range of techniques is even increasing. So, the extraperitoneal Sugarbaker that requires a transversus abdominis release seems to be very appropriate for robotic use with up to now promising results^[42]. However, Tastaldi *et al.*, very familiar with any form of component separation techniques, stopped this technique, done by them in an open approach due to the unacceptable complication rate^[46]. In 38 patients with a median observation time of 13 months, mesh erosion took place in three patients (8%), and the recurrence rate was 11%. So, the hype using robotics in all possible cases is comprehensible but should be used with caution. Furthermore, a strict follow-up of patients treated by new methods is indispensable.

The last but important aspect concerns the textile structures used for repair as it is in the prevention of parastomal hernia. As outlined above, there is increasing experimental and clinical evidence that polyvinylidene fluoride is superior to the widely used polypropylene, as outlined in the “prevention” section. Furthermore, only covered polypropylene-based meshes may be used intraperitoneally. Up to now, there is no available data on what happens with the covered meshes overlying each other, which is necessary when using the sandwich technique. Also, the funnel-like 3-dimensional mesh is made by polyvinylidene fluoride and is only available as Dynamesh IPST[®] or Dynamesh IPST R[®]. Therefore, the most effective approaches of the prevention and treatment of parastomal hernias, which are intraperitoneal mesh-based procedures, can only be done using meshes made by polyvinylidene fluoride.

CONCLUSION

The parastomal hernia significantly impairs the quality of life of patients. Therefore, preventive measures are necessary. Inconsistent results of available studies can be explained by methodological and technical aspects. Assuming adequate study design, an eventual parastomal hernia should be diagnosed clinically and by CT. A long-term follow-up is needed, and, most important, the keyhole technique must be analyzed separately from the intraperitoneal chimney technique using 3-dimensional implants with a funnel surrounding the stoma-related bowel. The implantation technique must be strictly standardized. The same facts are true for the repair of parastomal hernia. The clinical results are far from satisfying, and a lot of

different methods are described. Due to the low caseload of single surgeons, a sufficient comparison of these techniques is almost impossible. Therefore, the repair must be concentrated in specialized centers to increase the caseload, providing adequate expertise and allowing studies comparing different approaches using a strictly standardized surgical technique. Nevertheless, the intraperitoneal sandwich technique seems to be the most effective one. For some reasons outlined above, polyvinylidene fluoride-based meshes must be used for the chimney and the sandwich technique.

DECLARATIONS

Author's contribution

Wrote the article, conducted the literature search, and provided the figures: Berger D

Availability of data and materials

Not applicable.

Financial support and sponsorship

Not applicable.

Conflicts of interest

Prof. Dieter Berger is “Medical Advisor” and “Trainer” of “Listo.academy”, which is powered by Dynamesh.

Ethical approval and consent to participate

Not applicable.

Consent for publication

Not applicable.

Copyright

© The Author(s) 2023.

REFERENCES

1. Londono-Schimmer EE, Leong AP, Phillips RK. Life table analysis of stomal complications following colostomy. *Dis Colon Rectum* 1994;37:916-20. [DOI](#) [PubMed](#)
2. Leong AP, Londono-Schimmer EE, Phillips RK. Life-table analysis of stomal complications following ileostomy. *Br J Surg* 1994;81:727-9. [DOI](#) [PubMed](#)
3. Ambe PC, Kurz NR, Nitschke C, Odeh SF, Möslein G, Zirngibl H. Intestinal ostomy: classification, indications, ostomy care and complication management. *Dtsch Arztebl Int* 2018;115:182-7. [DOI](#) [PubMed](#) [PMC](#)
4. Maruo K, Tanaka T, Shindo T, et al. Incidence and risk factors of parastomal hernia after ileal conduit diversion in Japanese population. *Int J Clin Oncol* 2020;25:1830-4. [DOI](#)
5. Liu NW, Hackney JT, Gellhaus PT, et al. Incidence and risk factors of parastomal hernia in patients undergoing radical cystectomy and ileal conduit diversion. *J Urol* 2014;191:1313-8. [DOI](#)
6. Ghoreifi A, Allgood E, Whang G, et al. Risk factors and natural history of parastomal hernia after radical cystectomy and ileal conduit. *BJU Int* 2022;130:381-8. [DOI](#)
7. Feng D, Wang Z, Yang Y, Li D, Wei W, Li L. Incidence and risk factors of parastomal hernia after radical cystectomy and ileal conduit diversion: a systematic review and meta-analysis. *Transl Cancer Res* 2021;10:1389-98. [DOI](#) [PubMed](#) [PMC](#)
8. Dewulf M, Hildebrand ND, Bouwense SAW, Bouvy ND, Muysoms F. Parastomal hernias after cystectomy and ileal conduit urinary diversion: surgical treatment and the use of prophylactic mesh: a systematic review. *BMC Surg* 2022;22:118. [DOI](#) [PubMed](#) [PMC](#)
9. Moreno-Matias J, Serra-Aracil X, Darnell-Martin A, et al. The prevalence of parastomal hernia after formation of an end colostomy. A new clinico-radiological classification. *Colorectal Dis* 2009;11:173-7. [DOI](#)
10. Näsval P, Dahlstrand U, Löwenmark T, Rutegard J, Gunnarsson U, Strigard K. Quality of life in patients with a permanent stoma after rectal cancer surgery. *Qual Life Res* 2017;26:55-64. [DOI](#) [PubMed](#) [PMC](#)
11. Goffioul L, Bonnet P, Waltregny D, Detry O. Parastomal hernia after radical cystectomy with ileal conduit diversion: a narrative review. *Acta Chir Belg* 2021;121:373-9. [DOI](#) [PubMed](#)

12. Ripoche J, Basurko C, Fabbro-Perray P, Prudhomme M. Parastomal hernia. A study of the French federation of ostomy patients. *J Visc Surg* 2011;148:e435-41. DOI PubMed
13. Niu N, Du S, Yang D, et al. Risk factors for the development of a parastomal hernia in patients with enterostomy: a systematic review and meta-analysis. *Int J Colorectal Dis* 2022;37:507-19. DOI
14. Timmermans L, Deerenberg EB, van Dijk SM, et al. Abdominal rectus muscle atrophy and midline shift after colostomy creation. *Surgery* 2014;155:696-701. DOI
15. Nagayoshi K, Nagai S, Hisano K, Mizuuchi Y, Fujita H, Nakamura M. Atrophic change of the abdominal rectus muscle significantly influences the onset of parastomal hernias beyond existing risk factors after end colostomy. *Hernia* 2021;25:141-8. DOI PubMed
16. Helgstrand F, Rosenberg J, Kehlet H, Jorgensen LN, Wara P, Bisgaard T. Risk of morbidity, mortality, and recurrence after parastomal hernia repair: a nationwide study. *Dis Colon Rectum* 2013;56:1265-72. DOI PubMed
17. Kroese LF, Lambrichts DPV, Jeekel J, et al. Non-operative treatment as a strategy for patients with parastomal hernia: a multicentre, retrospective cohort study. *Colorectal Dis* 2018;20:545-51. DOI
18. Luo J, Singh D, Zhang F, et al. Comparison of the extraperitoneal and transperitoneal routes for permanent colostomy: a meta-analysis with RCTs and systematic review. *World J Surg Oncol* 2022;20:82. DOI PubMed PMC
19. Hardt J, Meerpohl JJ, Metzendorf MI, Kienle P, Post S, Herrle F. Lateral paraarectal versus transrectal stoma placement for prevention of parastomal herniation. *Cochrane Database Syst Rev* 2019;4:CD009487. DOI PubMed PMC
20. Jänes A, Cengiz Y, Israelsson LA. Preventing parastomal hernia with a prosthetic mesh: a randomized study. *Arch Surg* 2004;139:1356-8. DOI PubMed
21. Antoniou SA, Agresta F, Garcia Alaminó JM, et al. European hernia society guidelines on prevention and treatment of parastomal hernias. *Hernia* 2018;22:183-98. DOI
22. Prudhomme M, Fabbro-Peray P, Rullier E, Océan BV, Bertrand MM. Meta-analysis and systematic review of the use of a prosthetic mesh for prevention of parastomal hernia. *Ann Surg* 2021;274:20-8. DOI PubMed
23. McKechnie T, Lee J, Lee Y, et al. Prophylactic mesh for prevention of parastomal hernia following end colostomy: an updated systematic review and meta-analysis of randomized controlled trials. *J Gastrointest Surg* 2022;26:486-502. DOI
24. de Smet GHJ, Lambrichts DPV, van den Hoek S, et al. Comparison of different modalities for the diagnosis of parastomal hernia: a systematic review. *Int J Colorectal Dis* 2020;35:199-212. DOI
25. Vierimaa M, Klintrup K, Biancari F, et al. Prospective, randomized study on the use of a prosthetic mesh for prevention of parastomal hernia of permanent colostomy. *Dis Colon Rectum* 2015;58:943-9. DOI
26. Brandsma HT, Hansson BM, Aufenacker TJ, et al; Dutch Prevent Study group. Prophylactic mesh placement during formation of an end-colostomy long term Rct on effectiveness and safety. *Ann Surg* 2023;278:e440-6. DOI
27. Garcia-Alaminó JM, López-Cano M, Kroese L, Helgstrand F, Muysoms F. Quality assessment and risk of bias of systematic reviews of prophylactic mesh for parastomal hernia prevention using amstar and robis tools. *World J Surg* 2019;43:3003-12. DOI PubMed
28. Klinge U, Klosterhalfen B. Mesh implants for hernia repair: an update. *Expert Rev Med Devices* 2018;15:735-46. DOI PubMed
29. Eickhoff R, Heise D, Kroh A, et al. Improved tissue integration of a new elastic intraperitoneal stoma mesh prosthesis. *J Biomed Mater Res B Appl Biomater* 2020;108:2250-7. DOI
30. Köhler G. Principles and parallels of prevention and repair of parastomal hernia with meshes. *Chirurg* 2020;91:245-51. DOI PubMed
31. Mäkäriäinen-Uhlbäck E, Wiik H, Kössi J, Nikberg M, Ohtonen P, Rautio T. Chimney Trial: study protocol for a randomized controlled trial. *Trials* 2019;20:652. DOI PubMed PMC
32. Tabusa H, Blazeby JM, Blencowe N, et al. Protocol for the UK cohort study to investigate the prevention of parastomal hernia (the CIPHER study). *Colorectal Dis* 2021;23:1900-8. DOI
33. Williams NS, Hotouras A, Bhan C, Murphy J, Chan CL. A case-controlled pilot study assessing the safety and efficacy of the Stapled Mesh stomA Reinforcement Technique (SMART) in reducing the incidence of parastomal herniation. *Hernia* 2015;19:949-54. DOI PubMed
34. Mohiuddin S, Reeves BC, Smart NJ, Hollingworth W; CIPHER study group. A semi-Markov model comparing the lifetime cost-effectiveness of mesh prophylaxis to prevent parastomal hernia in patients undergoing end colostomy creation for rectal cancer. *Colorectal Dis* 2021;23:2967-79. DOI PubMed
35. Henriksen NA, Mortensen JH, Lorentzen L, et al. Abdominal wall hernias-A local manifestation of systemically impaired quality of the extracellular matrix. *Surgery* 2016;160:220-7. DOI
36. Zhao F, Chen F, Yuan X, Liu Y, Chen J. Decreased collagen type III synthesis in skin fibroblasts is associated with parastomal hernia following colostomy. *Int J Mol Med* 2019;44:1609-18. DOI PubMed PMC
37. Hansson BM, Slater NJ, van der Velden AS, et al. Surgical techniques for parastomal hernia repair: a systematic review of the literature. *Ann Surg* 2012;255:685-95. DOI
38. Sugarbaker PH. Peritoneal approach to prosthetic mesh repair of paraostomy hernias. *Ann Surg* 1985;201:344-6. DOI PubMed PMC
39. LeBlanc KA, Bellanger DE, Whitaker JM, Hausmann MG. Laparoscopic parastomal hernia repair. *Hernia* 2005;9:140-4. DOI PubMed
40. Berger D, Bientzle M. Laparoscopic repair of parastomal hernias: a single surgeon's experience in 66 patients. *Dis Colon Rectum* 2007;50:1668-73. DOI PubMed
41. Pauli EM, Juza RM, Winder JS. How I do it: novel parastomal herniorrhaphy utilizing transversus abdominis release. *Hernia* 2016;20:547-52. DOI

42. Dewulf M, Dietz UA, Montgomery A, et al. Robotic hernia surgery IV. English version: robotic parastomal hernia repair. Video report and preliminary results. *Chirurgie (Heidelb)* 2022;93:129-40. DOI PubMed PMC
43. Fischer I, Wundsam H, Mitteregger M, Köhler G. Parastomal hernia repair with a 3d funnel intraperitoneal mesh device and same-sided stoma relocation: results of 56 cases. *World J Surg* 2017;41:3212-7. DOI PubMed
44. Mäkäräinen-Uhlbäck E, Vironen J, Falenius V, et al. Parastomal hernia: a retrospective nationwide cohort study comparing different techniques with long-term follow-up. *World J Surg* 2021;45:1742-9. DOI PubMed PMC
45. Helgstrand F, Henriksen NA. Outcomes of parastomal hernia repair after national centralization. *Br J Surg* 2022;110:60-6. DOI PubMed
46. Tastaldi L, Haskins IN, Perez AJ, Prabhu AS, Rosenblatt S, Rosen MJ. Single center experience with the modified retromuscular Sugarbaker technique for parastomal hernia repair. *Hernia* 2017;21:941-9. DOI PubMed