

# Parastomal hernia repair with a 3-D mesh device and additional flat mesh repair of the abdominal wall

G. Köhler · O. O. Koch · S. A. Antoniou ·  
M. Lechner · F. Mayer · U. Klinge ·  
K. Emmanuel

Received: 16 November 2013 / Accepted: 28 July 2014 / Published online: 12 August 2014  
© Springer-Verlag France 2014

## Abstract

**Purpose** Parastomal hernias (PSHs) have been a major clinical problem. The aim of this study was to evaluate a new method of PSH repair in combination with an additional flat mesh reinforcement of the abdominal wall.

**Methods** In a pilot case series, seven patients suffering from complex PSHs ( $\geq 5$  cm diameter and/or recurrence) underwent surgery and were treated by intraperitoneal onlay technique (IPOM) with a synthetic 3-D funnel-shaped mesh implant. The demographics, perioperative, and follow-up data are presented in this report.

**Results** The surgical strategy varied between purely laparoscopic ( $n = 1$ ), laparoscopically assisted (hybrid  $n = 3$ ), or open techniques ( $n = 3$ ) using original or

suture-reconstructed mesh devices. The funnel mesh implantations in IPOM technique were combined with attached flat meshes in the appropriate position of the abdominal wall. No procedure-related complications occurred. The mean length of hospital stay was 12 days and the mean operating time was 171 min. No recurrence of PSH or incisional hernias was observed during a mean follow-up period of 12.3 months (range from 7 to 22).

**Conclusion** The use of a 3-D mesh implant has so far shown to be a promising option in the treatment of primary and recurrent PSHs. Its use proved to be reasonable in both laparoscopic and open IPOM technique. PSHs were preferably repaired using the original, unmodified implant, but when we also found it safe to incise, place and then suture the mesh around the pre-existing ostomy.

G. Köhler (✉) · O. O. Koch · K. Emmanuel  
Department of General and Visceral Surgery, Sisters of Charity Hospital, 4010 Linz, Austria  
e-mail: gernot.koehler@bhs.at

G. Köhler · O. O. Koch · K. Emmanuel  
Academic Teaching Hospital of the Universities of Graz, Graz, Austria

G. Köhler · O. O. Koch · K. Emmanuel  
Academic Teaching Hospital of the Universities of Innsbruck, Innsbruck, Austria

S. A. Antoniou  
Center for Minimally Invasive Surgery, Hospital Neuwerk, Moenchengladbach, Germany

M. Lechner · F. Mayer  
Department of Surgery, Paracelsus Medical University, Salzburg, Austria

U. Klinge  
Department of General, Visceral and Transplantation Surgery, RWTH Aachen University, Aachen, Germany

**Keywords** Parastomal hernia · Abdominal wall hernia · Intraperitoneal onlay mesh

## Introduction

Parastomal hernias (PSHs) are a common and major clinical problem after permanent stoma formation with a reported incidence of up to 50 % in clinical examination and even 78 % when looked for with the help of computed tomography [1]. A specific surgical technique, which could help to dramatically reduce the hernia incidence is not defined, not least reflecting that the epidemiology of incisional hernias (IH) and PSH development are based on impaired local wound healing [2]. At least 30 % of patients with PSH require surgical repair due to associated complications or complaints [3]. The high prevalence of PSH, clinical impairment, and the disappointing results of PSH repair make it clear that initial prevention of hernia-

formation would indeed be desirable. The only effective way to avoid PSH formation is a mesh reinforcement of the abdominal wall around the stoma [4]. Accordingly Berger reported promising results for PSH prevention using a specially designed 3-D intraperitoneal onlay mesh (Dynamesh<sup>TM</sup>, IPST<sup>®</sup>) in a prospective study [5].

For patients who already have developed a PSH, a repair with a combination of flat meshes (so called Sandwich technique, combining “keyhole” with “Sugarbaker”) is considered to be most effective [6]. The use of a “Keyhole-mesh” only is associated with a high risk of recurrence through the central mesh defect [7] and the “Sugarbaker” technique alone, despite its large mesh-area covering the lateralized bowel, does not provide a closure of the hernia defect itself [8, 9]. The “sandwich technique”, however, often raises concern because of the sharp edges of the keyhole mesh which might lead to erosion of the bowel, and because of the functional change in bowel anatomy due to the lateralisation that may lead to bowel obstruction. In the presence of recurrent PSH, especially after previous attempts of mesh repair, the laparoscopic sandwich technique is often hampered by adhesions and scar tissue formation. Looking at the excellent results of PSH prevention with a 3-D funnel device to keep the bowel with reinforcement of the surrounding tissues [5], we assumed that the use of this device may also be beneficial in the repair of PSHs, as well, if combined with a satisfying reinforcement of the midline with an additional flat intraperitoneal onlay mesh (IPOM). We report our experience how a pre-shaped and elastic 3-D funnel device can be used for the repair of PSHs. In the seven cases evaluated, we either used the mesh as provided by the manufacturer (when the colostomy needed to be repositioned) or cut the mesh and funnel, placed it around the bowel and over the PSH defect as desired and then re-established its integrity by non-absorbable suture when the original colostomy was decided to be left in its initial position in the abdominal wall.

## Material and method

From May 2012 to October 2013, we prospectively evaluated 7 cases of complex (fascia gap  $\geq 5$  cm, hernia defect area  $\geq 25$  cm<sup>2</sup> and/or recurrence) PSHs which were repaired with a 3-D, funnel-shaped mesh at the Sisters of Charity Hospital’s department of General and Visceral Surgery, Linz. Apart from a thorough clinical examination preoperative diagnostics were based on a dynamic abdominal computed tomography scan during which patients performed an abdominal thrust maneuver. This allowed for better visualization of the abdominal wall defect and the hernia’s content. All PSHs were then graded according to the radiological classification of Moreno-

Matias and the new European Hernia Society (EHS) classification [10, 11]. Since in our experience complex PSHs with or without concomitant IH frequently require a tailored approach the surgical technique applied was carefully adapted to the actual intraoperative findings. The surgical strategy varied between laparoscopic, laparoscopically assisted (hybrid), or open techniques and the funnel mesh implantations in intraperitoneal onlay technique were combined with attached flat meshes in the appropriate position of the abdominal wall. All seven procedures were performed by a single surgeon with a special professional interest in hernia surgery. In all cases a 3-D, funnel-shaped and macro-porous monofilament mesh (Dynamesh<sup>TM</sup>, IPST<sup>®</sup>, FEG Textiltechnik, Aachen, Germany) consisting of visceral-sided polyvinylidene fluoride (PVDF) and parietal-sided polypropylene (PP) was placed in either open or laparoscopic IPOM technique and secured with an absorbable strap device (Ethicon<sup>TM</sup>, Secure Strap<sup>®</sup>) in double crown technique at the edges of the flat part of the mesh and around the funnel. In 6 of our 7 patients (pat. A, B, C, D, E and G) with previous midline laparotomy additional flat meshes were used to reinforce the abdominal wall irrespective of the presence of an incisional hernia. The remaining patient’s (pat. F) abdominal midline was reinforced with the flat part of the funnel-shaped mesh in the course of a laparotomy that became necessary due to a chronic abscess of the pelvis. It was performed as an open IPOM technique. In all cases of laparoscopic procedures the additionally used flat PVDF/PP meshes (Dynamesh<sup>TM</sup> IPOM<sup>®</sup>, FEG Textiltechnik, Aachen, Germany) were placed as IPOMs, fixed with absorbable strap devices. To ensure permanent interconnection of the two meshes, areas where the two implants overlapped were secured with non-absorbable spiral tacks (Covidien<sup>TM</sup>, protack<sup>®</sup>). Whenever the presence of a concomitant incisional hernia made us decide in favour of an open surgical approach, an additional flat polyester mesh (Parietex<sup>®</sup>, Covidien<sup>TM</sup>) was placed according to the individual surgical strategy in either sublay [12] or onlay [13] position. We gained formal consent from all our patients in writing for anonymised collection and analysis of data as well as for the publication of the study’s results. Data were collected from the prospective “Herniamed<sup>®</sup> registry” [14] and the institution’s medical records (SAP) and medical files.

Patients’ demographics and disease characteristics including concomitant incisional hernias (graded in accordance to the EHS classification for ventral hernias [15]), previous abdominal operations, American Society of Anesthesiologists (ASA) score, body-mass index (BMI), hernia-specific risk factors and comorbidities (use of anti-coagulants or intake of acetylsalicylic acid, pre-existing coagulopathy, corticosteroid intake, diabetes, chronic obstructive pulmonary disease (COPD), medicamentous

immunosuppression and nicotine dependence) were documented according to the Herniamed-protocol [14]. Primary and recurrent PSHs were distinguished. In the presence of an ostomy, potential abdominal wall contamination was always considered. All patients received a single dose of sulfamicyllin 3 g half an hour before surgery.

Primary and patient relevant outcome endpoints were successful treatment with the initially planned procedure, intra- and postoperative complications and recurrences during the follow-up period. Three weeks after discharge, all patients were subject to a first follow-up in a face-to-face patient interview as well as with a clinical and sonographical examination. In addition, 6 months after surgery all patients were examined with an abdominal computed tomography (CT) at rest and during Valsalva's maneuver. The further follow-up was designed to consist of 6-monthly appointments with interviews and clinical examinations as well as an annually abdominal CT scan. Follow-up data for all patients with malignant disease were collected in accordance with the S3 guideline [16]. Standardized oncological aftercare is scheduled quarterly during the first 2 years and semiannually thereafter for up to 5 years. Only descriptive statistics were used.

## Results

We report on our initial experience of elective complex PSH repair with a 3-D mesh, which was initially designed for PSH prevention (square meshes with a side length of 15 or 16 cm; funnel diameter: 2 or 3 cm). The patients had in common a terminal left-sided colostomy.

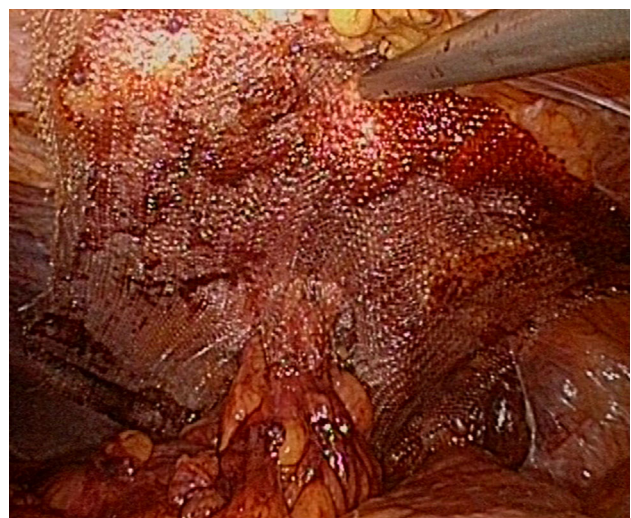
Three patients had laparoscopically assisted surgery (pat. A, B, C).

*Patient A* required a contralateral stoma translocation because of a PSH with a  $10 \times 4$  cm abdominal wall defect and poor ipsilateral tissue texture. We opted for an open approach on the site of the colostomy and adhesiolysis followed by reduction of the hernia sac content and excision of the hernia sac itself. The then mobilized colon was brought through the funnel mesh and then shifted to the contralateral side of the abdomen by sliding a hand into the abdominal cavity. Thus, only a small skin incision at the new stoma site was required and a wall re-laparotomy in the midline could be avoided. Midline and sutured former stoma site were reinforced with flat PVDF mesh in laparoscopic IPOM technique. The funnel mesh was also secured laparoscopically with absorbable fixation devices. On closer examination, the funnel mesh in this special case was used in order to prevent a PSH at the new ostomy site. The pre-existing scar in the midline and the sutured fascia

defect in the initial ostomy location were widely overlapped with an additional intraperitoneally placed  $20 \times 20$  cm PVDF/PP flat mesh. The patient could be discharged on the 10th postoperative day, but needed re-admission due to an infected seroma at the initial ostomy site on the 26th postoperative day. The collection was drained under local anaesthesia and the patient remained on the ward for another 8 days.

*Patient B and C* both underwent ipsilateral stoma revision due to PSH recurrences after previous “keyhole” and “onlay” mesh-based PSH repair. Initially laparoscopic adhesiolysis was attempted, but strong adhesions of the large bowel to the keyhole mesh and intense scarring inside a large hernia sac impeded safe dissection and required conversion to a small, localized open procedure at the stoma site in both cases. The ostomy itself was then closed by suture and an open adhesiolysis, hernial sac excision without jeopardizing the integrity of the bowel itself. The keyhole mesh was resected from the abdominal wall in order to avoid a local accumulation of mesh material, which was considered as a threat to the integration of the new implant into the abdominal wall. The shortened colon was then brought out through the  $15 \times 15$  cm square, three-dimensional funnel mesh. After the hernia defect in the abdominal wall was narrowed by suture the bowel was re-fixedated in the previous position and opened to complete the new ostomy. Eventually, the mesh was laparoscopically secured to the inside of the abdominal wall by absorbable strap devices (Fig. 1).

*One patient (G)* suffering from a lateral PSH defect underwent a purely laparoscopic parastomal hernia repair without re-ostomy. The fascial defect was narrowed by three transfascial sutures using a suture-passer. The incised



**Fig. 1** Laparoscopic view on IPST<sup>®</sup> mesh after equi-lateral re-ostomy

funnel mesh was brought into the abdominal cavity through the 12 mm port and after spreading it out around the stomal bowel, the 3-D design was reconstructed with non-absorbable interrupted sutures.

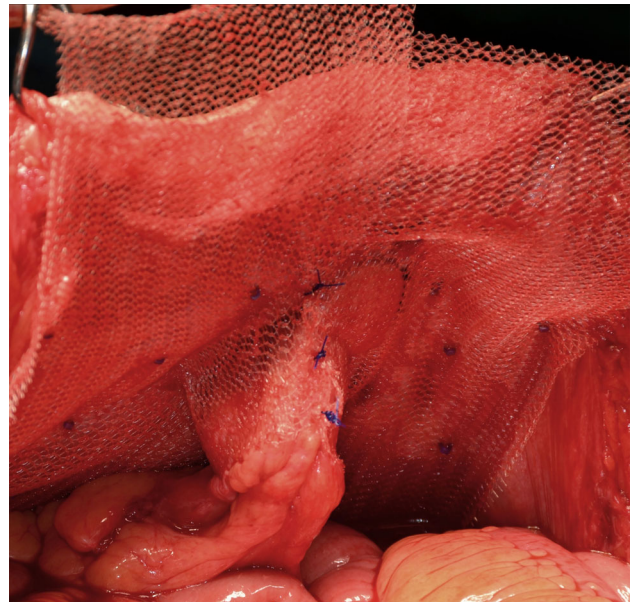
All these above-mentioned procedures included curative or preventive reinforcement of a former midline incision with (Patient G) or without manifest incisional hernia (Patient A, B, C) by the use of additional flat and suitable trimmed PVDF/PP meshes in IPOM technique.

The remaining three patients required an open approach (pat. D, E, F).

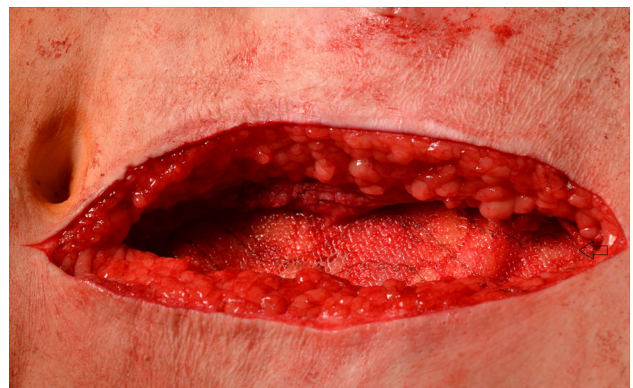Two patients (D, E) presented with large concomitant incisional midline hernias (EHS: W3/  $\geq 10$  cm in width). In *patient D* an open abdominal wall reconstruction with a 30 × 20 cm polyester sublay mesh accompanied by a modified posterior component separation (right sided transversus abdominis muscle release) was performed. At the stoma site, the posterior rectus sheath was incised and detached from the rectus muscle to the muscle's lateral edge at the semilunar line. In this patient, the ostomy was initially localized far outside the lateral border of the left rectus muscle and therefore, placement of the intraperitoneal funnel mesh without re-ostomy formation was possible without compromising the flat mesh sublay repair. The PSH defect was narrowed with interrupted non-absorbable sutures from intraperitoneal. The 3-D mesh was incised, positioned around the stoma and sutured with non-absorbable running sutures. The mesh was thereafter secured to the lateral abdominal wall in open IPOM technique with absorbable fixation devices.

*Patient E* required an anterior component separation with “onlay” mesh placement because of an incisional hernia recurrence after previously performed “sublay” mesh repair. The ostomy was recreated ipsilaterally through a newly created outlet on the left side of the abdominal wall and it was protected by an unmodified 3-D funnel mesh. The new formation of the new ostomy had become necessary because of the lateral abdominal wall's extensive shift towards the midline during the anterior component separation and the 30 × 30 cm “onlay” polyester mesh had to be widely incised for the new stoma's opening.

*Patient F* required a lower midline laparotomy for surgical treatment of a chronic abscess in the pelvis caused by a recto-vesical fistula. We opted for PSH repair without re-ostomy. The incised 3-D mesh was placed intraperitoneally, wrapped around the bowel at the stoma site and it was reconstructed with non-absorbable sutures (Fig. 2). The medial edge of the implant's flat part was armed with non-absorbable sutures 3 cm from each other to achieve mesh-based reinforcement of the midline in open IPOM



**Fig. 2** Reconstructed and closed funnel mesh around a left stoma bowel after cutting of the funnel in open surgery



**Fig. 3** Before closing the midline laparotomy the 3-D funnel mesh was used for additional reinforcement of the midline in open IPOM technique

technique (Fig. 3). The sutures were brought out through the abdominal wall on the right side of the midline incision with a suture-passer to ensure reinforcement of the laparotomy. Therefore, this was the only patient who required no additional separate flat mesh for midline reinforcement. On the 1st postoperative day, the patient unfortunately had to undergo a second urological procedure because of a urinary bladder leak that eventually led to a nephrostomy.

Patients' demographics and disease characteristics, intra- and perioperative parameters, postoperative complications, outcome, and follow-up parameters are depicted in Tables 1, 2, and 3. Apart from one serosal bowel damage in patient B, which was noted and repaired laparoscopically no intraoperative complications occurred. During the

**Table 1** Patients' demographic and disease characteristics

Patient	Age (years)	Gender	BMI (kg/m <sup>2</sup> )	ASA (1–4)	EHS Risk-factors <sup>a</sup>	Previous operations <sup>b</sup>	VAS preop. (0–10) <sup>c</sup>	Coincident incisional hernia (EHS) <sup>d</sup>
A	83	Female	33.6	3	1, 2, 6	5	6	–
B	51	Male	31.1	2	3	5,11	3	–
C	74	Male	32.6	2	2	5,11	3	–
D	69	Male	27.8	2	2	5	3	P/M2–4/W3
E	73	Female	25.8	2		5, 10	4	R1/M2–4/W3
F	76	Male	24.6	3	2, 3	5	7	–
G	66	Male	26.4	2	1, 6	5, 11	3	P/M3–4/W1
Mean	70.3		28.8	2.3			4.1	

<sup>a</sup> “Herniated protocol<sup>®</sup>” [14]: Risk factors in hernia surgery: (1) Diabetes mellitus, (2) COPD, (3) Nicotine dependence, (4) Coagulopathy, (5) Cumarine, (6) ASS (acetylsalicylic acid), (7) Aortic aneurysm, (8) Immunosuppression, (9) Corticosteroids

<sup>b</sup> Previous operations: (1) Stomach/small bowel (2) Liver (3) Pancreas (4) Gallbladder (5) Large bowel/rectum (6) Splenic (7) Kidney (8) Aorta (9) Womb (10) Ventral hernia, (11) Parastomal hernia

<sup>c</sup> VAS visual analogue scale: measurement instrument for subjective pain

<sup>d</sup> EHS classification of median incisional hernias [15]: *P* primary, *R* recurrence; *M1* subxiphoidal, *M2* epigastric, *M3* umbilical, *M4* infraumbilical, *M5* suprapubical, *W* width; *W1* <4 cm, *W2* = 4–10 cm, *W3* >10 cm

**Table 2** Patients' disease and perioperative characteristics

Patient	Surgical technique	OP Duration (min)	PSH Primary/recurrence <sup>a</sup> Moreno–Matias Classification <sup>b</sup> EHS Classification <sup>c</sup>	PSH defect size (cm <sup>2</sup> )	Effective size of funnel mesh (cm <sup>2</sup> )	Size (cm <sup>2</sup> ) and position of the additional flat mesh for midline reinforcement
A	Lap. assisted contralateral translocation	130	P/MM III/EHS III	40	225	400, IPOM (PVDF/PP)
B	Lap. assisted ipsilateral relocation	150	R2 (1,3)/MM III/EHS I	20	180	200, IPOM (PVDF/PP)
C	Lap. assisted ipsilateral relocation	180	R2 (1,3)/MM III/EHS III	30	225	375, IPOM (PVDF/PP)
D	Open post. comp. separation + incised mesh around the stoma	240	P/MM II/EHS IV	24	150	600, Sublay (Polyester)
E	Open ant. comp. separation + ipsilateral relocation	180	R1 (2)/MM II/EHS IV	24	150	900, Onlay (Polyester)
F	Midline laparotomy + incised mesh around the stoma	240	P/MM II/EHS III	36	225	IPOM-midline reinforcement with the flat part of the funnel mesh (PVDF/PP)
G	Purely laparoscopic incised mesh repair	80	R1 (1)/MM I/EHS IV	24	256	250, IPOM (PVDF/PP)
Mean		171		28.3	201.6	454.2

<sup>a</sup> Parastomal hernia: *P* primary, *R* recurrence, *I* first, 2 second (*I* after onlay-repair, 2 after sublay-repair, 3 after keyhole-repair, 4 after sugarbaker-repair, 5 after sandwich-repair (combination of keyhole and sugarbaker))

<sup>b</sup> Moreno–Matias classification of parastomal hernias [10]: *0* normal, *I* hernial sac containing stoma loop, *II* Sac containing omentum, *III* Sac containing a loop other than stoma

<sup>c</sup> EHS classification of parastomal hernias [11] (small is ≤5 cm, *cIH* concomitant incisional hernia); *Type I* small PSH without *cIH*, *Type II* small PSH with *cIH*, *Type III* large PSH without *cIH*, *Type IV* large PSH with *cIH*

**Table 3** Patients' outcome and early follow-up characteristics

Patients	Intraoperative complication	Postoperative complications <30 days	Clavien–Dindo classification <sup>a</sup>		Length of stay (days)	VAS before discharge (0–10) <sup>b</sup>	IH or PSH Recurrence during follow-up	Follow-up (months)
A	No	Yes	IIIa	Re-admission	18	4	No	22
B	Serosal bowel damage	No			8	2	No	15
C	No	No			8	2	No	7
D	No	No			7	2	No	10
E	No	No			8	2	No	16
F	No	Yes	IIIb	Re-operation	29	4	No	9
G	No	No			6	2	No	7
Mean					12	2.6		12.3

<sup>a</sup> Clavien Dindo Classification of surgical complications: Dindo D, Demartines N, Clavien PA. Classification of surgical complications: a new proposal with evaluation in a cohort of 6,336 patients and results of a survey. *Ann Surg.* 2004;240(2):205–13

<sup>b</sup> VAS visual analogue scale: measurement instrument for subjective pain

follow-up period of a mean 12.3 months (range from 7 to 22 months), no clinical or radiological PSH- or IH recurrence occurred. All 7 patients underwent a CT scan 6 months after surgery and so far 3 patients were scanned after 1 year. An annually CT scan and semiannually physical examination are scheduled for a period of 5 years for all patients with funnel mesh PSH repair. No mesh-related complications and no postoperative alterations in bowel-habits, potentially caused by tightly fitting funnels, were recorded. No stoma complications like prolapse, retraction, fistula, bleeding, necrosis or skin irritations had to be observed.

## Discussion

Despite continuous progress in operative techniques, PSHs remain a daunting surgical challenge [17]. Several different surgical procedures are currently used for their repair, but many complications and considerable recurrence rates have been reported [18]. It has been shown that laparoscopic PSH repair using a “keyhole” technique in which a mesh with a central hole is positioned around the bowel to close the hernia is afflicted with a high recurrence rate [7]. From an anatomical point of view, flat meshes with a central hole, however placed, cannot sufficiently cover the edge areas of the stoma where the hernias occur [19]. We assume that flat meshes with a central hole are not the ideal way of prevention or treatment of a PSH. In cases of ventral/incisional hernias with a defect size of more than >10 cm in width (pat. D, E), we opted for an open approach rather than for alternatively performed IPOM mesh-bridging operations [20]. Our technique of choice is the sublay-mesh repair, which was firstly introduced by Jean Rives [12]. If the rectus muscle complex

cannot be adequately approximated to the midline after detachment of the posterior rectus sheaths, a modified posterior component separation (Transversus abdominis muscle release–TAR) can be performed [21]. Patient E required an anterior component separation [22] because of inseparable retro-muscular layers after previously preformed sublay-mesh repair of a midline hernia.

It has been experimentally shown that the elastic PVDF mesh material grows into the abdominal wall and prevents intestinal adhesions [23]. Based on these results we also chose to use this material for PSH repair. As of now our preferred standard technique for PSH repair is the laparoscopically assisted (hybrid) relocation of the stoma under protection of a 3-D mesh device combined with an additional flat mesh reinforcement of the abdominal wall (pat. B and C). This combination may be regarded as an alternative to the combined laparoscopic flat mesh-based “keyhole and Sugarbaker” or “Sandwich” procedure, initially described by Berger [6]. Even though this procedure was reported to be highly effective it has several limitations, not least because it mainly needs the laparoscopic approach. The sandwich technique requires sometimes extensive surgical experience due to a potentially very difficult dissection and may therefore be reserved for dedicated specialists. We believe that our approach may be more convenient as a standard procedure for the underlying issue and that it is useful in a variety of different situations. In cases of complex PSH, a purely laparoscopic technique might not always be feasible. Possible limitations of this method are dense adhesions that render the laparoscopic approach impossible. Furthermore PSH recurrences with exceptionally heavy tissue scarring, bowel adhesions after previously attempted PSH mesh repairs and the impossibility to reduce or mobilize a large hernia and its sac's content may limit its

use. A lateral position of a fascia defect, however, is also a weak point of the “sandwich” repair since neither with “keyhole”, nor with “Sugarbaker” technique lateral parastomal defects can be covered well [7, 9].

We embarked on a pilot use of IPST<sup>®</sup> mesh for PSH repair in an indeed heterogenous group of patients, but complex abdominal wall defects, in particular ones that include a PSH and a midline hernia require a tailored and flexible approach. We used to employ the 15 cm square mesh with a central funnel of 2 cm in width and a dome around it, which fits tightly around the bowel and must be oriented to the visceral side. The implant can be stretched to even bring a bulky stoma bowel through a 2 cm funnel with ease. In order to gain more overlap, a 16 cm square mesh with a central funnel of 3 cm in diameter was used in patient G. Based on the published experience of Jänes et al. [24], who performed PSH prevention even in the presence of peritonitis without increased rates of infections, we did not regard an abscess in the pelvis as a contraindication for PSH mesh repair in patient F. Even the sole presence of an ostomy and in particular its relocation must be judged as potential contamination of the abdominal wall. The results of all studies and reviews regarding PSH prevention by means of mesh implantation in different designs and positions relative to the layers of the abdominal wall showed no increased infection rates or mesh-related complications [4, 24–26].

We describe a promising and innovative way of treatment that—based on our experience with the 3-D funnel mesh implant—appears to provide great benefits for both prevention and treatment of PSH compared to other commonly performed procedures. Reasons for this observation include the following points:

- (1) IPST<sup>®</sup> can be used in laparoscopy, in laparoscopically assisted, and in open surgery.
- (2) The PSH defect can be covered locally with a wide overlap to all sides. This is an advantage compared to the open sublay technique for PSH repair which usually requires an additional midline laparotomy and in which the mesh placement is confined by the midline and lateral border of the rectus muscle [26].
- (3) By using a second flat mesh, areas with potentially insufficient overlap can be reinforced, and a pre-existing midline incisions can be well covered to treat concomitant incisional hernias or avoid their occurrence [6].
- (4) The positive effect on prolapse prevention arises from the dome, which is directed towards the abdominal cavity and fits to the bowel tightly [5].
- (5) The local fascia does not need to be approximated with close contact to the bowel, even though this is the area in which PSHs commonly occur. With

IPST<sup>®</sup> it is possible to make an incision into the anterior or posterior fascia that is large enough to easily bring even a bulky stoma out through the abdominal wall, while the fascia defect remains well covered by a mesh with sufficient overlap.

- (6) Wound complications like hematoma and infections should in theory decrease since the layers of the abdominal wall do not need to be separated. Moreover, the dissection of the posterior rectus sheath for sublay repair of PSH might not always be feasible because of scarring after previous operations [4].
- (7) The ipsilateral stoma reformation provides advantages over the usually performed IPOM technique. Firstly the localized approach easily allows for complete excision of the hernia sac for seroma prevention and secondly the narrowing of the fascia defect provides a better “landing zone” for the underlying flat part of the funnel mesh and therefore prevents pseudo-recurrence due to mesh bulging.
- (8) The implant can be placed easily and quickly [5]. At the end of a long operation when PSH prevention is indicated, the factor of time must not be neglected because of the naturally occurring mental and physical fatigue of the surgical team. Furthermore time saving is expected for PSH repair with 3-D funnel mesh compared to complex “Sandwich” and “Sublay” techniques.
- (9) If it is necessary the ostomy can be brought out through the lateral abdominal wall. It is no longer imperative to bring out the bowel through the rectus muscle. The rationale for routing the stoma through the rectus muscle is to avoid stomal prolapse and PSH formation which are hardly influenced by this routine anyway. Both complications can essentially be decreased by using a 3-D funnel mesh.
- (10) When a new ostomy is created, the bowel can easily be brought out through the mesh, however, if surgeons decide to leave an ostomy unchanged, the 3-D mesh can be incised and reconstructed by non-absorbable sutures. Both techniques can be performed as either laparoscopic or open surgery.
- (11) Potential drawbacks of the “sandwich technique” are avoided. These are the potentially sharp edges of the flat “keyhole” mesh that may lead to local bowel erosion. In the intact funnel mesh the edges of the opening are less likely to cause these complications since the fibres of the dome are moulded into a perpendicular configuration and therefore run parallel to the bowel. The anatomical change in bowel configuration due to the lateral

deviation with the risk of obstruction caused by the “Sugarbaker” mesh can be avoided.

To date no long-term follow-up data are available to examine the efficacy of the procedure or the recurrence rates. A potential drawback of all the techniques described could be the close contact of the bowel to the mesh funnel. It cannot be ruled out that complications like erosion, fibrosis, and stenosis might occur in the long term. However, the original implant with its seamless extension into the intestinal cuff offers superb elasticity and flexibility. An incised 3-D mesh with interrupted texture may potentially not provide this durable firmness, elasticity and stretch. Cutting the funnel and sewing it may probably lead to disruption of the suture line and recurrent hernia later on. Looked at more closely it can then in principle be seen as a simple keyhole—repair [7, 19]. In addition a sutured PVDF/PP mesh always has sharp edges that can erode into the stoma loop. However, our experience indicates that cutting the funnel, wrapping it around the bowel and the closure of the cuff with sutures are an option, which—at least during the current follow-up period—seems not to compromise the results. Hence the IPST<sup>®</sup> can in theory also be used in patients with a well functioning ostomy without the need for relocation or reformation. Nevertheless, we do prefer to use the implant as provided by the manufacturer and we do not intentionally avoid ostomy procedures regardless of the ostomy’s function, because a small circular incision around the bowel opening provides ipsilateral reformation in exactly the same position without additional predetermined weakness.

In conclusion, the initial evaluation of 3-D funnel mesh use not for PSH prevention, but for PSH repair shows encouraging results for different types of abdominal wall defects and should be examined further. The laparoscopic or open approach and the funnel mesh implantation in intraperitoneal onlay technique in combination with attached flat meshes in the appropriate position of the abdominal wall offer a feasible and safe surgical alternative for repair of all kinds of PSH and concomitant incisional hernias. A longer follow-up period is needed for definitive conclusions to be drawn regarding the recurrence rate—especially in view of differences between uninterrupted and suture-reconstructed funnel meshes. The laparoscopically assisted, ipsilateral stoma-recreation through the original seamless funnel mesh is considered to be the most promising technique.

**Conflict of interest** GK declares no conflict of interest. OK declares no conflict of interest. SA declares no conflict of interest. ML declares no conflict of interest. FM declares no conflict of interest. UK declares conflict of interest not directly to the submitted work (consulting and/or speaking fees and expert testimony in the field of mesh surgery from FEG Aachen, Life Cell Corp., CR Bard Inc., Ethicon). KE declares no conflict of interest.

## References

- Cingi A, Cakir T, Sever A, Aktan AO (2006) Enterostomy site hernias: a clinical and computerized tomographic evaluation. *Dis Colon Rectum* 49(10):1559–1563
- Klinge U, Binnebösel M, Rosch R, Mertens P (2006) Hernia recurrence as a problem of biology and collagen. *J Minim Access Surg* 2(3):151–154
- Rieger N, Moore J, Hewett P, Lee S, Stephens J (2004) Parastomal hernia repair. *Colorectal Dis* 6(3):203–205
- Jänes A, Cengiz Y, Israelsson LA (2004) Randomized clinical trial of the use of a prosthetic mesh to prevent parastomal hernia. *Br J Surg* 91(3):280–282
- Berger D (2008) Prevention of parastomal hernias by prophylactic use of a specially designed intraperitoneal onlay mesh (Dynamesh IPST). *Hernia* 12(3):243–246
- Berger D (2010) Laparoscopic repair of parastomal hernia. *Chirurg* 81(11):988–992
- Hansson BM, Bleichrodt RP, de Hingh IH (2009) Laparoscopic parastomal hernia repair using a keyhole technique results in a high recurrence rate. *Surg Endosc* 23(7):1456–1459
- Berger D, Bientzle M (2007) Laparoscopic repair of parastomal hernias: a single surgeon’s experience in 66 patients. *Dis Colon Rectum* 50:1668–1673
- Sugarbaker PH (1985) Peritoneal approach to prosthetic mesh repair of paraostomy hernias. *Ann Surg* 201:344–346
- Moreno-Matias J, Serra-Aracil X, Darnell-Martin A, Bombardo-Junca J, Mora-Lopez L, Alcantara-Moral M, Rebasa P, Ayguavives-Garnica I, Navarro-Soto S (2009) The prevalence of parastomal hernia after formation of an end colostomy. A new clinico-radiological classification. *Colorectal Dis* 11(2):173–177
- Smietanski M, Szczepkowski M, Alexandre JA, Berger D, Bury K, Conze J, Hansson B, Janes A, Miserez M, Mandala V, Montgomery A, Morales Conde S, Muysoms F (2014) European Hernia Society classification of parastomal hernias. *Hernia* 18:1–6
- Rives J, Lardennois B, Pire JC, Hibon J (1973) Large incisional hernias. The importance of flail abdomen and of subsequent respiratory disorders. *Chirurgie* 99:547–563
- Chevreil JP (1979) The treatment of large midline incisional hernias by “overcoat” plasty and prosthesis. *Nouv Presse Med* 8(9):695–696
- Stechemesser B, Jacob DA, Schug-Paß C, Köckerling F (2012) Herniamed: an internet-based registry for outcome research in hernia surgery. *Hernia* 16(3):269–276
- Muysoms FE, Miserez M, Berrevoet F, Campanelli G, Champault GG, Chelala E, Dietz UA, Eker HH, El Nakadi I, Hauters P, Hidalgo Pascual M, Hoferlin A, Klinge U, Montgomery A, Simmermacher RK, Simons MP, Smietanski M, Sommeling C, Tollens T, Vierendeels T, Kingsnorth A (2009) Classification of primary and incisional abdominal wall hernias. *Hernia* 13(4):407–414
- Schmiegel W, Reinacher-Schick A, Arnold D, Graeven U, Heinemann V, Porschen R, Riemann J, Rödel C, Sauer R, Wieser M, Schmitt W, Schmoll HJ, Seufferlein T, Kopp I, Pox C (2008) Update S3-guideline “colorectal cancer” 2008. *Z Gastroenterol* 46(8):799–840
- Rosch R, Junge K, Böhm G, Conze J, Schumpelick V (2008) Surgical treatment and prophylaxis of parastomal hernias]. *Zentralbl Chir* 133(5):464–467
- Carme PW, Robertson GM, Frizelle FA (2003) Parastomal hernia. *Br J Surg* 90(7):784–793
- Hansson BM, Slater NJ, van der Velden AS, Groenewoud HM, Buys OR, de Hingh IH, Bleichrodt RP (2012) Surgical

- techniques for parastomal hernia repair: a systematic review of the literature. *Ann Surg* 255(4):685–695
20. LeBlanc KA, Booth WV (1993) Laparoscopic repair of incisional abdominal hernias using expanded polytetrafluoroethylene: preliminary findings. *Surg Laparosc Endosc* 3:39–41
  21. Novitsky YW, Elliott HL, Orenstein SB, Rosen MJ (2012) Transversus abdominis muscle release: a novel approach to posterior component separation during complex abdominal wall reconstruction. *Am J Surg* 204(5):709–716
  22. Ramirez OM, Ruas E, Dellon AL (1990) Component separation method for closure of abdominal-wall defects: an anatomic and clinical study. *Plast Reconstr Surg* 86(3):519–526
  23. Klinge U, Klosterhalfen B, Ottinger AP, Junge K, Schumpelick V (2002) PVDF as a new polymer for the construction of surgical meshes. *Biomaterials* 23(16):3487–3493
  24. Jänes A, Cengiz Y, Israelsson LA (2010) Experiences with a prophylactic mesh in 93 consecutive ostomies. *World J Surg* 34(7):1637–1640
  25. Tam KW, Wei PL, Kuo LJ, Wu CH (2010) Systematic review of the use of a mesh to prevent parastomal hernia. *World J Surg* 34(11):2723–2729
  26. Serra-Aracil X, Bombardo-Junca J, Moreno-Matias J, Darnell A, Mora-Lopez L, Alcantara-Moral M, Ayguavives-Garnica I, Navarro-Soto S (2009) Randomized, controlled, prospective trial of the use of a mesh to prevent parastomal hernia. *Ann Surg* 249(4):583–587